



Ultrasonography versus Radiography in Detection of Different Foreign Bodies in a Cadaveric Calf Thigh Specimen

MOHAMED GOMAA^{1*}, AHMED ABDELAAL²

¹*Surgery Department, Faculty of Veterinary Medicine, Zagazig University, Egypt;* ²*Animal Medicine Department, Faculty of Veterinary Medicine, Zagazig University, Egypt.*

Abstract | The current study was carried out to identify the ability of both radiography and ultrasonography in identifying the presence of some foreign bodies in a Cadaveric calf thigh specimen. Five different foreign bodies (metal, stone, glass, plastic and wood) were inserted separately in a freshly thawed cadaveric calf thigh muscle. Two different imaging modalities were applied, firstly, conventional plain radiography and secondly, ultrasonography. In general, metals, stones and glass were radiopaque. On the other hand, plastics and wooden objects could not be detected by conventional plain radiography. Meanwhile by ultrasound examination, all foreign bodies appeared as hyperechoic structure with distal artifacts. Reverberation artifacts (comet tail) appeared clearly with metal and glass materials. While, distal acoustic shadowing was obvious in stones, plastics and wooden objects. Ultrasound in this study proved to be brilliant for detection of radiolucent foreign bodies as plastic and wood. For radiopaque foreign bodies, ultrasound can provide more accurate localization and also the artifact distal to foreign bodies played an important role in detecting the nature and surface properties of these foreign bodies.

Keywords | Ultrasonography, Radiography, Foreign Bodies, Cadaveric Calf Thigh

Editor | Muhammad Abubakar, National Veterinary Laboratories, Islamabad, Pakistan.

Received | November 30, 2015; **Revised** | December 13, 2015; **Accepted** | December 16, 2015; **Published** | January 27, 2016

***Correspondence** | Mohamed Gomaa, Zagazig University, Egypt; **Email:** Gomaasurgeon@yahoo.com

Citation | Gomaa M, Abdelaal A (2015). Ultrasonography versus radiography in detection of different foreign bodies in a cadaveric calf thigh specimen. *Res. J. Vet. Pract.* 3(4): 83-88.

DOI | <http://dx.doi.org/10.14737/journal.rjvp/2015/3.4.83.88>

ISSN | 2308-2798

Copyright © 2015 Gomaa and Abdelaal. This is an open access article distributed under the Creative Commons Attribution License, which permits unrestricted use, distribution, and reproduction in any medium, provided the original work is properly cited.

INTRODUCTION

Foreign bodies can be defined as any objects originating outside the body (Eggers et al., 2007). The common organic materials like thorns, wood and sand constitute routine accident scene flora and comprise a large percentage of foreign bodies. These of low radiopacity make a diagnostic challenge and are routinely missed on standard radiography (Ipaktchi et al., 2013).

Gastrointestinal foreign bodies are common surgical emergencies in veterinary medicine. Cattle as well as buffaloes are susceptible to foreign body syndrome because they do not discriminate against metal materials in feed and do not completely masticate feed before swallowing (Mccurin and Bassar, 2006; Abdelaal, 2009). In small animals, balls are easily identified sonographically because of their characteristic curvilinear interface. Linear foreign bodies pres-

ent as bright linear interfaces, commonly associated with shadowing and the affected bowel segment often appears plicated (Penninck, 2008; Gomaa et al., 2012).

Traditionally, plain radiographs have been the first modality of choice for the diagnosis of foreign bodies. It is well documented that plain radiographs are successful in detecting radiopaque foreign bodies in the soft tissue (Flom and Ellis, 1992). However, radiolucent foreign bodies in the soft tissue could not be detected in all cases (Kjhns et al., 1979; Bodne et al., 1988; Graham, 2002; Venter et al., 2005). Usually the preferred visualizing technique is conventional plain radiography for detecting foreign bodies. Ultrasonography is helpful in visualizing suspected low radiopaque foreign objects. Thus, Initial Radiography supplemented by ultrasonography improve the detection rate of foreign bodies (Panigrahi et al., 2015).

Ultrasonography has been previously described as a sensitive technique for identifying foreign objects that are not radiographically visible. However, the diagnostic accuracy is variable because sonography is highly operator dependent. Foreign objects may also be obscured when they are surrounded by bone, air, dense fibrous tissue, or other tissue interfaces (Flom and Ellis, 1992; Manthey et al., 1996; Boyse et al., 2001; Holmes et al., 2005).

Non-opaque foreign bodies are visualized sonographically as hyperechoic foci with distal acoustic shadowing (Peterson et al., 2002). This shadow may be either complete or partial depending on angle of examination and composition of the foreign body (Anderson et al., 1982).

Ultrasonography has been introduced as an adjunct to the conventional plain radiographs for detecting and removing both radiopaque and radiolucent foreign bodies in soft tissue wounds (Turner et al., 1997; Blankenship and Baker, 2007). Ultrasound technique uses a high-frequency transducer to penetrate soft tissue for the localization and evaluation of foreign bodies (Boyse et al., 2001; Mills and Butts, 2009). By scanning the tissue in both longitudinal and transverse orientations, bright hyperechoic foci can be visualized indicating the presence of wooden, glass, and metal foreign bodies (Boyse et al., 2001).

Numerous studies were conducted on the topic of gastrointestinal foreign bodies but there was a lack in researches concerned soft tissue foreign bodies.

The purpose of this study was to determine the difference between radiography and ultrasonography in detecting different foreign bodies in a cadaveric calf thigh specimen.

MATERIAL AND METHODS

Five different materials made up of metal, stone, glass, plastic and wood were included. These foreign bodies were lodged separately in the thigh muscles of a freshly thawed calf hind limb after creating an incision of 5 cm length and 2 cm depth (Figure 1).

The metal objects included are Key, nails, and magnet, While, stones varied from smooth and rough surfaces stones and irregular and rectangular stones. Glass materials were a piece of glass and large and small glass balls. Plastics included were stiff tubules, irregular shaped plastic and a hose piece. Finally, wooden objects were a piece of wood, pencil fragment and a date pit.

Two different imaging modalities, conventional plain radiography and ultrasonography, were used to detect and specify the type of foreign body inserted in the thigh muscle. Lateromedial radiographic view was taken for the thigh

specimen containing all foreign bodies of the same material at the same time to compare their radiopacity using *Toshiba Rotanode (POX-300 BT, Japan) radiographic machine* with an exposure factors of 65 KV and 6.3 mA.s. Concerning ultrasonography, esaote MyLabOne Vet, Netherlands with linear transducer 7.5 MHz machine was used. Each foreign body was lodged in the thigh muscle and imaged alone. Finally, interpretation of the resulted image was done.

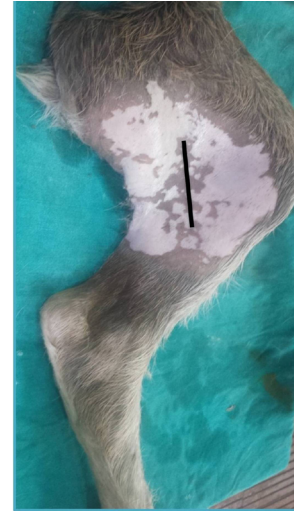

Figure 1: A cadaveric calf thigh specimen with the black line showed the seat of incision

RESULTS

Metals were clearly detected by both radiography and ultrasonography as radiopaque structures and hyperechoic (white) objects accompanied with distal reverberation (comet tail) artifact, respectively (Figure 2).

Stones appeared as less radiopaque objects than metals. In ultrasonographic image, hyperechoic objects were detected with either clean distal shadowing (irregular surface stones) or reverberation artifacts (stones with smooth and flat surfaces) (Figure 3).

Glass was clearly detected as less radiopaque structure than metal (Figure 4B). Ultrasonographically, they appeared as hyperechoic curvilinear objects with reverberation artifacts in case of glass balls and hyperechoic line with reverberation artifacts in case of glass piece (Figure 4).

Plastics were not detected radiographically except a faint radiopaque lines in case of a hose piece. During ultrasound examination, the plastic were readily apparent as hyperechoic curvilinear shapes in transverse scanning of tubular stiff plastic and a hose piece with clean distal shadowing. Irregular shaped plastic appeared as hyperechoic irregular structure with dirty distal shadowing (Figure 5).

By radiography, wooden objects were not detected except a faint radiopaque line in case of a pencil fragment that contained graphite inside. During ultrasound examination, the wood was readily apparent as hyperechoic structures with clean distal shadowing (Figure 6).

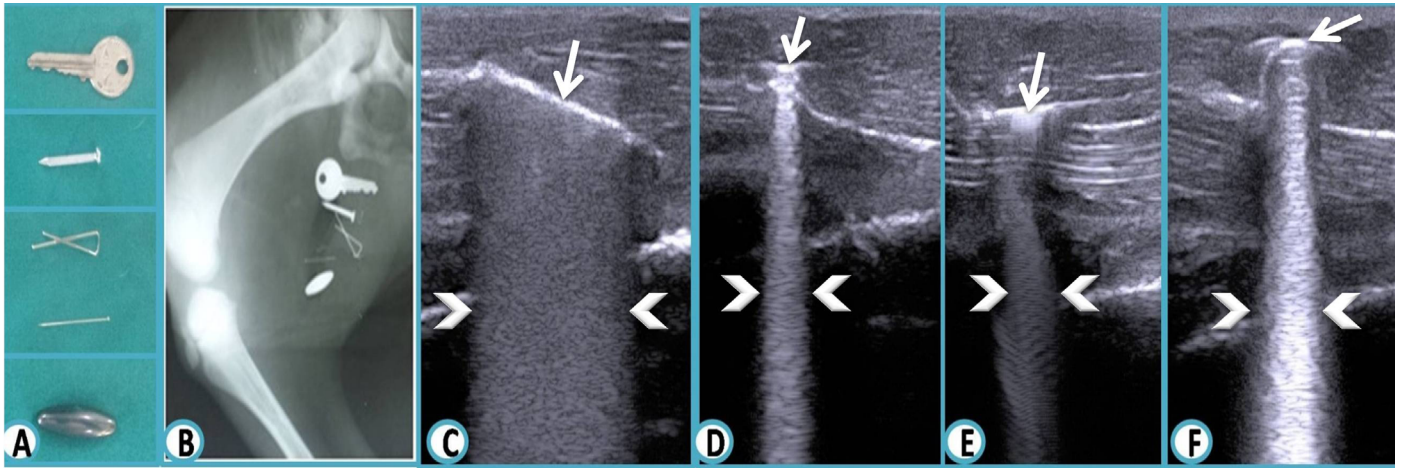


Figure 2: The metallic foreign bodies

A: Photograph shows the different metallic objects (Key, nails, magnet) before being placed in a cadaveric calf thigh specimen; **B:** Lateromedial radiograph shows radiopaque metallic foreign bodies; **C, D, E, F:** Ultrasound images reveal hyperechoic metallic objects (arrows). Note reverberation (comet tail artifact distally) (arrow heads).

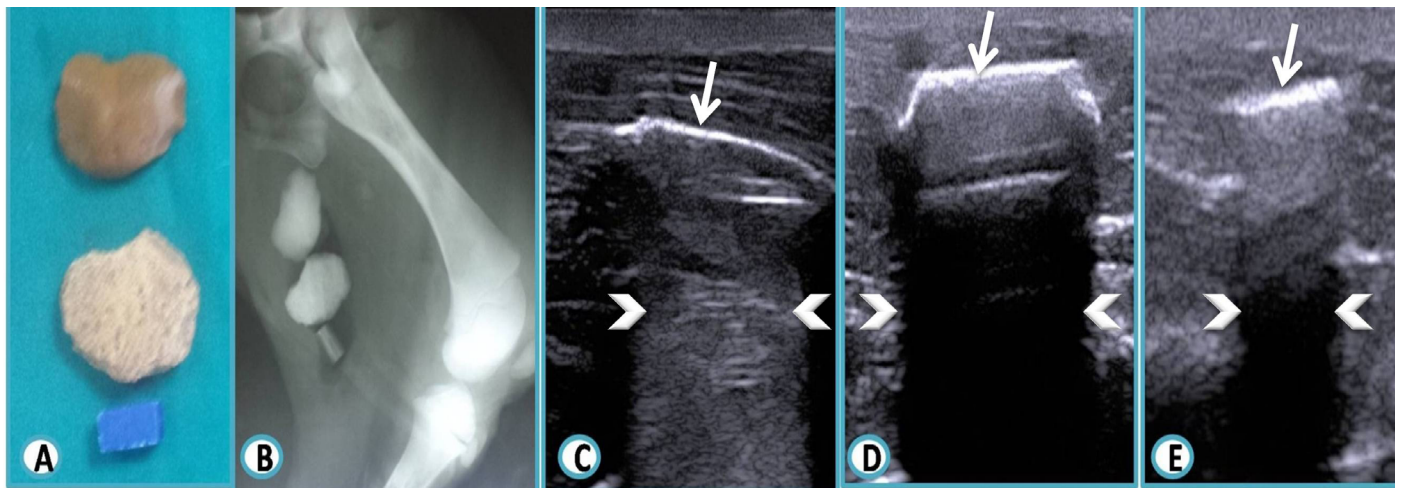


Figure 3: The stone foreign bodies

A: Photograph shows the different stone objects (smooth and rough surfaces and irregular and rectangular stones) before being placed in a cadaveric calf thigh specimen; **B:** Lateromedial radiograph shows radiopaque stone foreign bodies; **C:** Ultrasound image reveal hyperechoic stone object (arrow). Note reverberation (comet tail artifact distally) (arrow heads); **D, E:** Ultrasound images reveal hyperechoic stone objects (arrow). Note posterior acoustic shadowing (arrow heads) with minimal reverberation artifact.

DISCUSSION

Identifying the various types of foreign bodies requires an understanding not only of the properties of X-ray and ultrasound but also of the properties of the object itself. The appearance of foreign bodies varies with the shape and density of the material. In general, metal, stone, glass were clearly detected radiographically as radiopaque structures. Different foreign bodies exhibit different physical properties when displayed via different visualization techniques. A foreign body might be overlooked with one method and successfully detected with another (Oikarinen et al., 1993; Eggers et al., 2005; Mills and Butts, 2009).

In the current study, a non-radiopaque foreign body did not produce a signal on X-ray as wood and plastic. Hence, the composition of a foreign body determines whether it

is visible on the image or not, and whether its size can influence the intensity and dimensions on imaging or not (Eggers et al., 2007).

Radiography, the traditional method of confirming foreign bodies, can make precise localization difficult because it yields limited information on the depth and orientation of the object. If a foreign body is composed of non-radiopaque material such as wood or plastic, it may not be evident in plain radiographs at all (Mills and Butts, 2009). In contrast to ultrasound examination of wood and plastic, they appeared hyperechoic with clean distal acoustic shadowing as that appeared in this study.

The ultrasound artifact occurring deep to a foreign body depends primarily on its surface attributes rather than its composition. Smooth and flat surfaces produce dirty shad

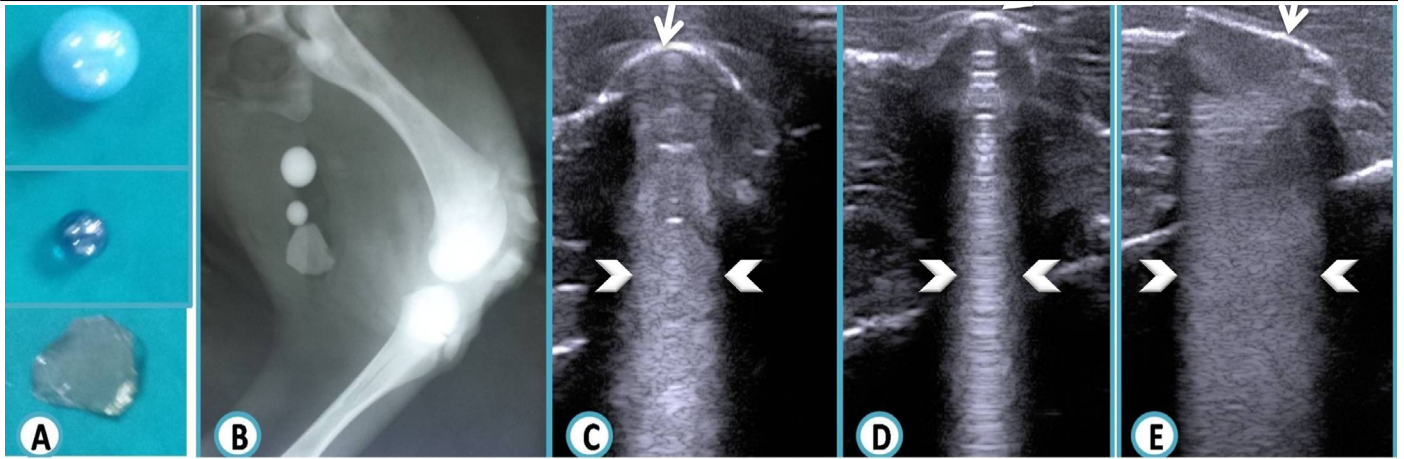


Figure 4: The glass foreign bodies

A: Photograph shows the different glass objects (large and small glass balls and a piece of glass) before being placed in a cadaveric calf thigh specimen; **B:** Lateromedial radiograph shows radiopaque glass foreign bodies; **C, D, E:** Ultrasound images reveal hyperechoic glass objects (arrows). Note reverberation (comet tail artifact distally) (arrow heads).

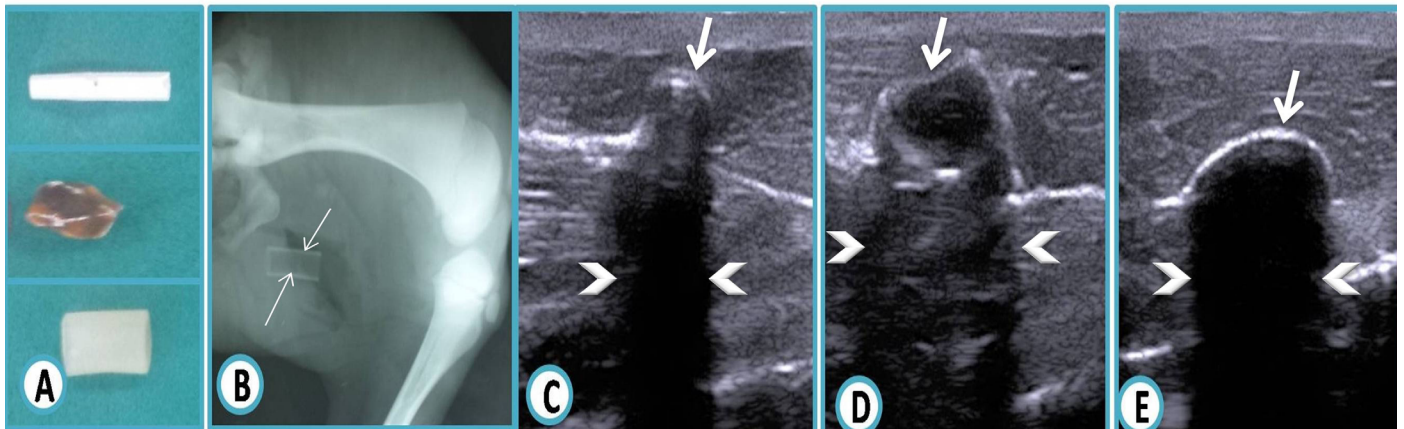


Figure 5: The plastic foreign bodies

A: Photograph shows the different plastic objects (stiff tubule, irregular shaped and hose piece plastic) before being placed in a cadaveric calf thigh specimen; **B:** Lateromedial radiograph does not show plastic foreign body except faint radiopaque lines of the hose piece (arrows); **C, D, E:** Ultrasound images reveal hyperechoic plastic objects (arrows). Note the marked clean distal acoustic shadowing (arrow heads) in (C, E) while in (D) irregular shaped plastic appeared as hyperechoic irregular structure with dirty distal shadowing.

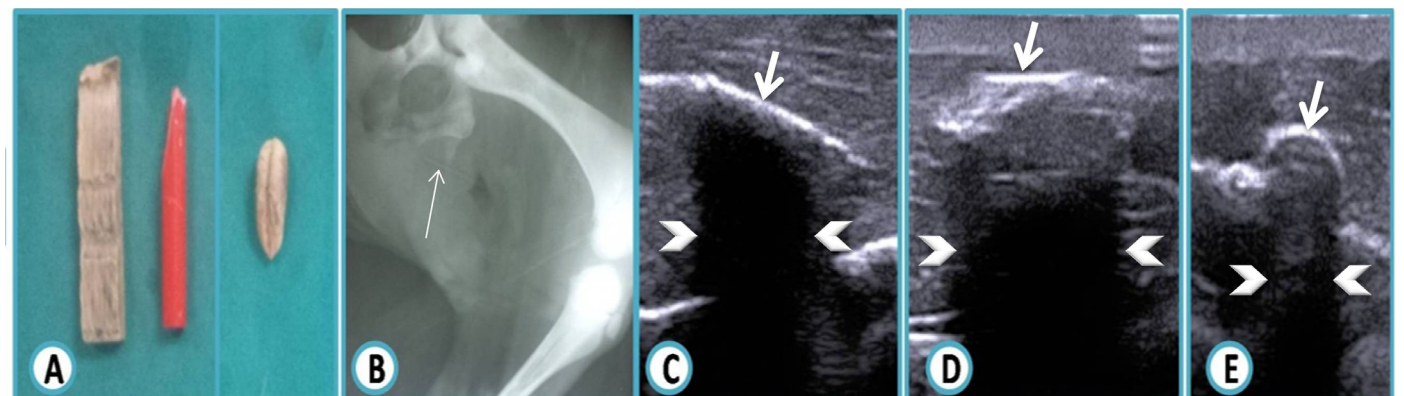


Figure 6: The wooden foreign bodies

A: Photograph shows the different wooden objects (a piece of wood, pencil fragment and a date pit) before being placed in a cadaveric calf thigh specimen; **B:** Lateromedial radiograph does not show wooden foreign body except in case of a pencil fragment appeared as centrally radiopaque, which represents graphite (arrow) and surrounding radiolucent area represents wood; **C:** Ultrasound image reveal hyperechoic wooden object (arrow). Note the marked clean distal acoustic shadowing (arrow heads); **D, E:** Ultrasound images reveal hyperechoic wooden objects (arrows). Note the marked clean distal acoustic shadowing (arrow heads) with minimal reverberation artifact.

owing or reverberation artifact, whereas irregular surfaces and those with a small radius of curvature produce clean shadowing. Metal and glass often demonstrate reverberation due to their flat surfaces. However, a flat surface not imaged perpendicular to the ultrasound beam may not produce reverberation, as was noted with a glass foreign body and a hypodermic needle. Some foreign bodies produce both clean and dirty shadowing (Rubin et al., 1991; Bray et al., 1995).

Comet tail artifact is a form of reverberation; therefore it has the same production basis, and repeated trips between the transducer and two reflective surfaces (Méndez Garrido et al., 2013).

A pencil fragment containing graphite as a radiopaque material was examined on radiography, appeared centrally radiopaque, which represented the graphite, surrounded by the more radiolucent wood. On ultrasound, the pencil was hyperechoic and showed complete posterior shadowing; the same result was obtained on the pictorial essay of (Horton et al. 2001).

In the current study, two foreign bodies were not appeared during radiographic examination, these were plastic and wood. Similar result was also mentioned in the study of Jacobson et al. (1998) as several soft tissue foreign bodies, such as wood and plastic, are not radiopaque and may remain undetected on radiography; and this is comparable with the study results of Anderson et al. (1982) and Levine et al. (2008) which showed that only 15% and 7% of radiolucent foreign bodies appeared in radiographic studies, respectively. This study suggests that ultrasound is a highly sensitive and accurate modality in detecting radiolucent foreign bodies that are difficult to be visualized on standard radiographs.

However, all foreign bodies are hyperechoic on sonography. Sonographic artifacts deep in relation to soft tissue foreign bodies are related to the surface attributes rather than the composition of the foreign body and aid in their identification.

Ultrasound is playing an increasing role in the diagnostic process, not only for the detection of nonopaque foreign bodies but also for the accurate localization of all types of soft tissue foreign bodies. Accurate localization can be valuable in minimizing surgical exploration, or, alternatively, real time sonographic visualization can guide percutaneous removal of a soft-tissue foreign body (Shiels et al., 1990).

CONCLUSION

Ultrasonography is a useful imaging modality in the diagnosis of different foreign bodies without the risk of ioniz-

ing radiation. Ultrasound is the study of choice for detection of radiolucent foreign bodies as plastic and wood. For radiopaque foreign bodies, ultrasound can provide more accurate localization and the artifact distal to foreign bodies played an important role in detection the nature and surface attributes of such foreign bodies.

CONFLICT OF INTEREST

The authors declare that they have no conflict of interest.

AUTHORS CONTRIBUTION

Both authors contributed equally in study design, radiographic and ultrasonographic interpretations, also in reviewing and editing the manuscript.

ACKNOWLEDGEMENT

The authors would like to thank all assistant lecturers in Surgery Department, Faculty of Veterinary Medicine, Zagazig University, Egypt for helping and contribution during the radiographic and ultrasonographic imaging.

REFERENCES

- Abdelaal AM, Floeck M, El Maghawry S, Baumgartner W (2009). Clinical and ultrasonographic differences between cattle and buffaloes with various sequelae of traumatic reticuloperitonitis. *Vet. Medicina*. 54: 399-406.
- Anderson MA, Newmeyer WL, Kilgore ES (1982). Diagnosis and treatment of retained foreign bodies in the hand. *Am. J. Surg.* 144: 63-67. [http://dx.doi.org/10.1016/0002-9610\(82\)90603-1](http://dx.doi.org/10.1016/0002-9610(82)90603-1)
- Blankenship RB, Baker T (2007). Imaging modalities in wounds and superficial skin infections. *Emerg. Med. Clin. N. Am.* 25: 223-234. <http://dx.doi.org/10.1016/j.emc.2007.01.011>
- Bodne D, Quinn SF, Cochran CF (1988). Imaging foreign glass and wooden bodies of the extremities with CT and MR. *J. Comput. Assist. Tomogr.* 12: 608-11. <http://dx.doi.org/10.1097/00004728-198807000-00013>
- Boyse TD, Fessell DP, Jacobson JA, Lin J, van Holsbeeck MT, Hayes CW (2001). US of soft-tissue foreign bodies and associated complications with surgical correlation. *Radio. Graph.* 21: 1251-1256.
- Bray PW, Mahoney JL, Campbell JP (1995). Sensitivity and specificity of ultrasound in diagnosis of foreign bodies in the hand. *J. Hand. Surg.* 20:661-666. [http://dx.doi.org/10.1016/S0363-5023\(05\)80287-4](http://dx.doi.org/10.1016/S0363-5023(05)80287-4)
- Eggers G, Mukhamadiev D, Hassfeld S (2005). Detection of foreign bodies of the head with digital volume tomography. *Dentomaxillofac. Radiol.* 34: 74-79. <http://dx.doi.org/10.1259/dmfr/22475468>
- Eggers G, Welzel T, Mukhamadiev D, Wortche R, Hassfeld S, Muhling J (2007). X-ray-based volumetric imaging of foreign bodies: A comparison of computed tomography and digital volume tomography. *J. Oral Maxillofac. Surg.* 65: 1880-1885. <http://dx.doi.org/10.1016/j.joms.2006.09.029>
- Flom LL, Ellis GL (1992). Radiologic evaluation of foreign

- bodies. *Emerg. Med. Clin. N. Am.* 10: 163-177.
- Gomaa M, Kramer M, Samy M, Omar M, Nefissa Mekkawy (2012). Ultrasonographic Findings of Most Common Surgical Disorders of Gastrointestinal Tract in Dogs and Cats. *Iranian J. Vet. Surg.* 7(2): 23-37.
 - Graham DD Jr (2002). Ultrasound in the emergency department: Detection of wooden foreign bodies in the soft tissues. *J. Emerg. Med.* 22: 75-9. [http://dx.doi.org/10.1016/S0736-4679\(01\)00440-1](http://dx.doi.org/10.1016/S0736-4679(01)00440-1)
 - Holmes PJ, Miller JR, Gutta R, Louis PJ (2005). Intraoperative imaging techniques: a guide to retrieval of foreign bodies. *Oral Surg. Oral Med. Oral Pathol. Oral Radiol. Endod.* 100: 614-618. <http://dx.doi.org/10.1016/j.tripleo.2005.02.072>
 - Horton LK, Jacobson JA, Powell A, Fessell DP, Hayes CW (2001). Sonography and radiography of soft-tissue foreign bodies. *Am. J. Roentgenol.* 176 (5):1155-1159. <http://dx.doi.org/10.2214/ajr.176.5.1761155>
 - Ipaktchi K, Mars AD, Park J, Ciarallo C, Livermore M, Banegas R (2013). Retained palmar foreign body presenting as a late hand infection: proposed diagnostic algorithm to detect radiolucent objects. *Patient Saf. Surg.* 7: 25-33. <http://dx.doi.org/10.1186/1754-9493-7-25>
 - Jacobson JA, Powell A, Craig JG, Bouffard JA, van Holsbeeck MT (1998). Wooden foreign bodies in soft tissue: detection at US. *Radiology.* 206: 45-48. <http://dx.doi.org/10.1148/radiology.206.1.9423650>
 - Kjhns LR, Borlaza GS, Seigel RS, Paramagul C, Berger PE (1979). An *in vitro* comparison of computed tomography, xerography, and radiography in the detection of soft tissue foreign bodies. *Radiology.* 132: 218- 219. <http://dx.doi.org/10.1148/132.1.218>
 - Levine MR, Gorman SM, Young CF, Courtney DM (2008). Clinical characteristics and management of wound foreign bodies in the ED. *Am. J. Emerg. Med.* 26: 918-22. <http://dx.doi.org/10.1016/j.ajem.2007.11.026>
 - Manthey DE, Storrow AB, Milbourn JM, Wagner BJ (1996). Ultrasound versus radiography in the detection of soft-tissue foreign bodies. *Ann. Emerg. Med.* 28: 7-9. [http://dx.doi.org/10.1016/S0196-0644\(96\)70130-0](http://dx.doi.org/10.1016/S0196-0644(96)70130-0)
 - Mccurin DM, Bassar JM (2006). *Clinical Text Book for Veterinary Technicians.* 6th ed. Elsevier Saunders. Pp. 224-244.
 - Méndez Garrido S, Arce Duran J, Talegón Meléndez, A Sevilla ES, Seville ES (2013). Ring-down versus comet tail: Two artifacts uncovered. *European Soc. Radiol.* Pp 1-17.
 - Mills LD, Butts C (2009). Capturing elusive foreign bodies with ultrasound. *Emerg. Med.* (00136654) 41: 36-42.
 - Oikarinen KS, Nieminen TM, Makarainen H, Pyhtinen J (1993). Visibility of foreign bodies in soft tissue in plain radiographs, computed tomography, magnetic resonance imaging, and ultrasound. An *in vitro* study. *Int. J. Oral Maxillofac. Surg.* 22: 119-124. [http://dx.doi.org/10.1016/S0901-5027\(05\)80818-5](http://dx.doi.org/10.1016/S0901-5027(05)80818-5)
 - Panigrahi R, Dash SK, Palo N, Priyadarshi A, Sahu SK, Biswal MR (2015). Foreign body detection in musculoskeletal injuries: A *in vitro* blinded study comparing sensitivity among digital radiography, ultrasonography, CT and magnetic resonance imaging. *Musculoskelet Regen.* 2: e649. <http://dx.doi.org/10.14800/mr.649>
 - Penninck D (2008). Gastrointestinal tract, chapter 8 In: *Atlas of small animal ultrasonography*, Penninck D, d'Anjou MA. Blackwell Publishing, Iowa. USA. Pp. 281-318.
 - Peterson JJ, Bancroft LW, Kransdorf MJ (2002). Wooden foreign bodies: imaging appearance. *Am. J. Roentgenol.* 178(3):557-62. <http://dx.doi.org/10.2214/ajr.178.3.1780557>
 - Rubin JA, Adler RS, Bude RO, Fowlkes JB, Carson PL (1991). Clean and dirty shadowing at US: a reappraisal. *Radiology.* 181: 231-236. <http://dx.doi.org/10.1148/radiology.181.1.1887037>
 - Shiels WE, Babcock DS, Wilson JL, Burch RA (1990). Localization and guided removal of soft-tissue foreign bodies with sonography. *Am. J. Roentgenol.* 155:1277-1281. <http://dx.doi.org/10.2214/ajr.155.6.2122680>
 - Turner J, Wilde CH, Hughes KC, Meilstrup JW, Manders EK (1997). Ultrasound-guided retrieval of small foreign objects in subcutaneous tissue. *Ann. Emerg. Med.* 29: 731-734.
 - Venter NG, Jamel N, Marques RG, Djahjah F, Mendonça Lde S (2005). Evaluation of radiological methods for detection of wood foreign body in animal model. *Acta Cir. Bras.* 20: 19-26.